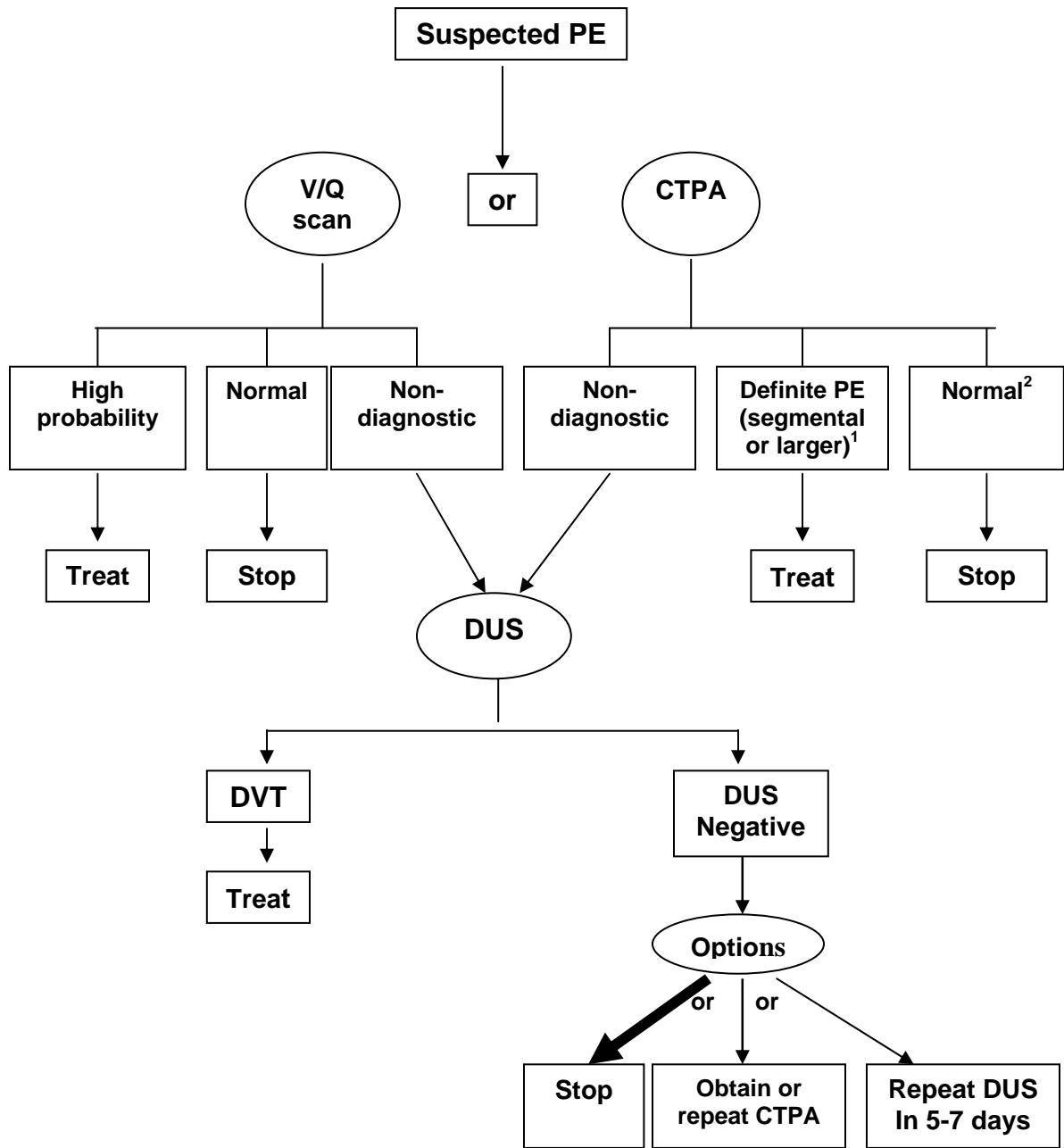


Figure 1: Investigation of Suspected PE Based on Imaging Tests Alone



1 A subsegmental filling defect on CTPA should generally be considered nondiagnostic

2 With a normal CTPA and a high clinical suspicion for PE, further testing should be considered